

Surgical Removal of Skull Base Meningiomas in Symptomatic Elderly Patients

Carlos Eduardo da Silva^{1,2} and Paulo Eduardo Peixoto de Freitas¹

■ **OBJECTIVE:** Meningiomas frequently occur in elderly patients, and surgical treatment is hazardous owing to multiple comorbidities. We report a series of elderly patients who were treated with surgical removal of meningiomas and compare them with a group of younger patients with similar tumors.

■ **METHODS:** A retrospective study of elderly patients with symptomatic skull base meningiomas and a matched control group of younger patients was performed. Medical records, operative reports, radiologic examinations, and follow-up data were reviewed. Main outcome measures were morbidity, mortality, and Simpson grade.

■ **RESULTS:** The study included 46 patients (23 elderly [age >65 years], 23 younger [age <65 years]). Average age was 71 years in elderly patients and 48 years in younger patients. Mean follow-up period was 32 months and 49 months, respectively. Radical removal (Simpson grades I and II) was observed in 83% and 91%, respectively. Mortality was 8% and 4%, respectively. Definite cranial nerve lesions occurred in 8% and 26%, respectively; cerebrospinal fluid leaks occurred in 12.5% and 4%, respectively; hemiparesis occurred in 4% of patients in both groups. Glasgow Outcome Scale score of 5 was obtained in 87% and 65.2%, respectively.

■ **CONCLUSIONS:** Elderly patients with symptomatic skull base meningiomas should be considered for surgical treatment owing to acceptable morbidity and mortality compared with younger patients. Previous comorbidities and involvement of neurovascular structures are important factors in the decision regarding extent of surgical resection.

INTRODUCTION

Skull base meningiomas are difficult lesions to treat when they insinuate among the cranial nerves and vital neurovascular structures. In elderly patients, comorbidities and age-related physiologic factors are additional concerns related to the selection of treatment strategy. At the present time, different protocols are applied to deal with such tumors, including simple observation, radiosurgery as the primary treatment, partial resection with radiosurgery as an adjuvant therapy, and aggressive surgical removal. Nevertheless, some skull base meningiomas with mass effect and involvement of the brainstem, cranial nerves, dural sinuses, or vascular structures require surgical removal even in older patients. We present our experience in the treatment of such difficult tumors in elderly patients in a surgery-oriented center.

MATERIALS AND METHODS

This study was approved by the local research ethic committee at Hospital Ernesto Dornelles (Comitê de Ética em Pesquisa No. 1.536.166). Patient information was de-identified before analysis. A retrospective study that included patients who were operated on between 2007 and 2015 was performed. In the elderly group, inclusion criteria were patients ≥ 65 years of age with symptomatic meningiomas of the anterior, middle, or posterior skull base operated on by the first author (C.E.S.). In the control group, patients ≤ 65 years of age who were operated on during the same period and who presented with similar tumors and surgical approaches were included. The data related to the surgical interventions were reviewed, and special attention was given to the Simpson grade and the site of the meningioma. We reviewed the medical records, operative reports, radiologic examinations, and follow-up information of the patients. All patients underwent surgery with the intent of the most extensive safe removal, including dural and bone invasions, considering the medical conditions and comorbidities of the patients.

Key words

- Elderly patients
- Meningioma
- Simpson grade
- Skull base
- Surgical treatment

Abbreviations and Acronyms

CSF: Cerebrospinal fluid

MRI: Magnetic resonance imaging

SKALE: Sex, Karnofsky performance scale, American Society of Anesthesiologists, location, and edema

WHO: World Health Organization

From the ¹Department of Neurosurgery and Skull Base Surgery, Hospital Ernesto Dornelles; and ²Division of Anatomy, Department of Basic Sciences of Health, Federal University of Health Sciences of Porto Alegre, Porto Alegre, Rio Grande do Sul, Brazil

To whom correspondence should be addressed: Carlos Eduardo da Silva, M.D., Ph.D.
[E-mail: carloseduardo@ufcspa.edu.br]

Citation: World Neurosurg. (2018).

<https://doi.org/10.1016/j.wneu.2018.09.024>

Journal homepage: www.WORLDNEUROSURGERY.org

Available online: www.sciencedirect.com

1878-8750/\$ - see front matter © 2018 Elsevier Inc. All rights reserved.

Several skull base approaches were used according to the site of the meningioma. Spheno-orbital meningiomas were removed via the cranio-orbital and cranio-orbital zygomatic approaches; petroclival meningiomas were removed through the posterior petrosal approach; tentorial meningiomas were removed through the transmastoid retrosigmoid and suboccipital approaches; olfactory groove, tuberculum sellae, and clinoidal meningiomas were removed via the cranio-orbital approach; temporal floor meningiomas were operated on through the subtemporal approach; and cerebellopontine angle meningiomas were removed through the transmastoid retrosigmoid approach.

Surgical Indications

All patients presented with ≥ 1 of the following features: documented growth on serial magnetic resonance imaging (MRI) evaluation, cranial nerve disturbances, brainstem compression, and arterial and venous invasion with clinical impairment.

Immediate Postoperative Protocol

In the immediate postoperative period, the patient is awakened in the operating room, extubation is performed, and the patient then stays in the intensive care unit for 24 hours. A computed tomography scan and MRI are performed during this period, and rehabilitation protocols that include early mobilization and intensive physiotherapy are implemented.

Statistical Analysis

Continuous data were described by mean and SD and compared using Student *t* test for paired samples. Categorical data were presented as counts and percentages and compared using McNemar or marginal homogeneity nonparametric tests with exact *P* values owing to the small counts involved. Significance level was set at $\alpha = 0.05$. Data were analyzed with IBM SPSS Version 22.0 (IBM Corp., Armonk, New York, USA).

RESULTS

Between 2007 and 2015, 23 skull base meningiomas in elderly patients were operated on. This group included the following lesions: 4 spheno-orbital, 4 petroclival, 4 tentorial, 4 olfactory groove, 2 clinoidal, 2 tuberculum sellae, 1 temporal floor, 1 sphenoid wing, and 1 cerebellopontine angle tumor. The group comprised 18 women and 5 men with an average age of 71 years (range, 65–87 years). The mean follow-up period was 32 months (range, 3–96 months). Simpson grades I and II were obtained after 83% of the surgeries; specifically, 29% of the lesions were Simpson grade I, and 54% were Simpson grade II. Meningiomas that had previously been irradiated accounted for 4% of cases. Meningiomas were > 3 cm in 75% of cases. The overall mortality was 8%. Definite cranial nerve deficits also occurred in 8% of cases. Cerebrospinal fluid (CSF) leaks occurred in 12.5% and hemiparesis occurred in 4% of cases.

During the same period, 86 patients with skull base meningiomas were operated on, including multiple sites, sizes, and surgical techniques. The younger matched group originated from this sample and included 23 consecutive similar skull base meningiomas with similar sizes and topography distribution to the elderly group. The group comprised 17 women and 6 men with an average

age of 48 years (range, 31–63 years). The mean follow-up period was 49 months (range, 3–144 months). Simpson grades I and II were obtained after 91% of the surgeries; specifically, 65% of the lesions were Simpson grade I, and 26% were Simpson grade II. Meningiomas that had previously been irradiated accounted for 8% of cases. Meningiomas were > 3 cm in 86% of cases. The overall mortality was 4%. Definite cranial nerve deficits also occurred in 26% of the cases. CSF leaks occurred in 4% and hemiparesis occurred in 4% of cases. **Tables 1** and **2** present the baseline findings of the groups and morbidity. During the postoperative follow-up period, 87% of the elderly patients obtained a Glasgow Outcome Scale score of 5 with return to normal life compared with 65.2% of the younger group.

DISCUSSION

Surgical Considerations

Reasonable surgical management of meningiomas in elderly patients should consider the general clinical condition of the patient and the morbidity of the treatment in this age group. Elderly patients with skull base meningiomas constitute a subgroup that is even more challenging in terms of surgical removal. The first aspect to be considered is the natural history of skull base meningiomas, which tend to manifest with a slower growth rate than non-skull base tumors; thus, in asymptomatic patients with incidental diagnoses, observation is a good and safe option.¹ During the same period in the present study, we followed 31 patients with asymptomatic meningiomas, including 20 patients ≥ 65 years of age.

All cases included in the surgical groups presented with ≥ 1 of the following features: documented growth on serial MRI evaluation, cranial nerve disturbances, brainstem compression, and arterial and venous invasion with clinical impairment. In asymptomatic elderly patients with skull base meningiomas, we usually follow the patients to clinically evaluate the evolution of the disease. Grading systems evaluating the risk of surgical treatment have been described, including SKALE (sex, Karnofsky performance scale, American Society of Anesthesiologists, location, and edema), Clinical-Radiological Grading System, and Geriatric Score System.² A study evaluating the Clinical-Radiological Grading System and SKALE system concluded that only concomitant disease and higher American Society of Anesthesiologists score significantly predicted mortality in such patients.³ These authors recommended making decisions on a case-by-case basis. Other authors have described excellent results of meningioma surgery in elderly patients compared with younger patients. The conclusions of these authors suggest that very careful selection of patients and surgical techniques and excellent preoperative and postoperative care by all the staff are needed.⁴

In our series, the meningioma topography was an important selection factor because skull base lesions are associated with a higher morbidity than non-skull base tumors. Considering patients with symptomatic skull base meningiomas, we believe that our results—8% mortality and a low rate of definite morbidity, with Glasgow Outcome Scale score 5 obtained in 87% of cases—were due not only to adequate surgical techniques but also to very careful preoperative evaluation involving clinical and cardiologic attention in addition to the preoperative preparation by the

Table 1. Characteristics of Elderly and Younger Groups with Skull Base Meningiomas

Characteristic	Age ≥65 (n = 23)	Age <65 (n = 23)	P Value
Age, years, mean ± SD	71.9 ± 5.9	48.0 ± 10.1	<0.001
Female sex, number (%)	18 (78.3)	17 (73.9)	>0.99
Site, number (%)			—
TEN	4 (17.4)	4 (17.4)	
SO	4 (17.4)	4 (17.4)	
PC	4 (17.4)	4 (17.4)	
OG	4 (17.4)	4 (17.4)	
TS	2 (8.7)	2 (8.7)	
CLIN	2 (8.7)	2 (8.7)	
TF	1 (4.3)	1 (4.3)	
SW	1 (4.3)	1 (4.3)	
CPA	1 (4.3)	1 (4.3)	
Approach, number (%)			—
CO	8 (34.8)	8 (34.8)	
COZ	5 (21.7)	5 (21.7)	
PP	4 (17.4)	4 (17.4)	
TMRS	4 (17.4)	4 (17.4)	
SOC	1 (4.3)	1 (4.3)	
ST	1 (4.3)	1 (4.3)	
Size, number (%)			0.063
<3 cm	6 (26.1)	3 (13.0)	
3–4 cm	16 (69.6)	13 (56.5)	
>4 cm	1 (4.3)	7 (30.4)	
Simpson grade, number (%)			0.031
I	7 (30.4)	15 (65.2)	
III	13 (56.5)	6 (26.1)	
≥III	3 (13.0)	2 (8.6)	
Previous surgical treatment, number (%)	4 (17.4)	3 (13.0)	>0.99
Previous radiotherapy, number (%)	1 (4.3)	1 (4.3)	—

TEN, tentorial; SO, sphenoid-orbital; PC, petroclival; OG, olfactory groove; TS, tuberculum sellae; CLIN, clinoidal; TF, temporal floor; SW, sphenoid wing; CPA, cerebellopontine angle; CO, cranio-orbital; COZ, cranio-orbital zygomatic; PP, posterior petrosal; TMRS, transmastoid retrosigmoid; SOC, suboccipital; ST, subtemporal.

anesthesiologist. In the postoperative period, we also implemented rehabilitation protocols that included early mobilization and intensive physiotherapy. Such protocols reduce the risk of long periods of bed rest and the associated dangerous effects in elderly patients. The patients are discharged from the intensive care unit in 24 hours, after the postoperative computed tomography scan. During the hospitalization period, we stimulate interaction with family members and begin multidisciplinary

Table 2. Comparative Results Between 2 Groups

Characteristic	Age ≥65 (n = 23)	Age <65 (n = 23)	P Value
Cranial nerve deficit	2 (8.7)	6 (26.1)	0.125
Hemiparesis	1 (4.3)	1 (4.3)	>0.99
CSF fistula	3 (13.0)	1 (4.3)	0.625
Death	2 (8.6)	1 (4.3)	>0.99

Data are presented as number (%).
CSF, cerebrospinal fluid.

support with physical therapists, social workers, psychologists and dietitians to prepare patients for prompt discharge.

The follow-up period is very important for evaluating any treatment modality for meningiomas. Short follow-up periods (<10 years) tend to result in overestimations of any therapeutic method.⁵⁻⁸ In elderly patients, the recurrence or progression of a benign meningioma should be considered to reduce life expectancy owing to comorbidities or natural aging. All surgical maneuvers and postoperative protocols should consider these factors.

With the exception of a few references in the literature,⁹ the consensus is that the most important contribution of surgery to meningioma control is the Simpson grade resection.¹⁰⁻¹⁶ We believe that true total removal (Simpson grade I) is difficult to achieve for skull base meningiomas. Our center is surgery-oriented in the treatment of meningiomas, although radiosurgery and fractionated radiation are available; thus, total removal is our initial goal, including for lesions located in the skull base. In a recent study, we presented our results regarding the treatment of large and giant meningiomas in which we achieved Simpson grade I resection in 45% of the cases.¹⁶ In the subgroup of elderly patients, we achieved Simpson grade I resection in 29% of the cases because we avoided aggressively manipulating arterial encasements and cranial nerve involvement of the tumors to maintain high quality of life and independence of the patients. We obtained Simpson grade II resection in 54% of the elderly patients. Even with such a conservative approach, CSF leaks were more frequent in the elderly group owing to dural fragility. Endoscopic endonasal and keyhole supraorbital approaches are interesting alternatives for minimally invasive management of skull base lesions. Nevertheless, for skull base meningiomas, we prefer larger exposures to obtain a safer dissection and a higher level of total removal around the optic apparatus, cavernous sinus, and petroclival region. We use the same routine for elderly patients without additional morbidities.

Figures 1 and 2 illustrate 2 cases from the elderly group. In the control group of younger patients, we obtained Simpson grade I in 65% and grade II in 26%. Such efforts to obtain total removal explain the higher incidence of cranial nerve deficits (26%) in the younger group.

The 8% mortality in the elderly group was related to a patient who presented with a large olfactory groove meningioma. This patient underwent the cranio-orbital approach and total tumor resection, which resulted in a fatal pulmonary thromboembolism during the postoperative period. A second patient with a large

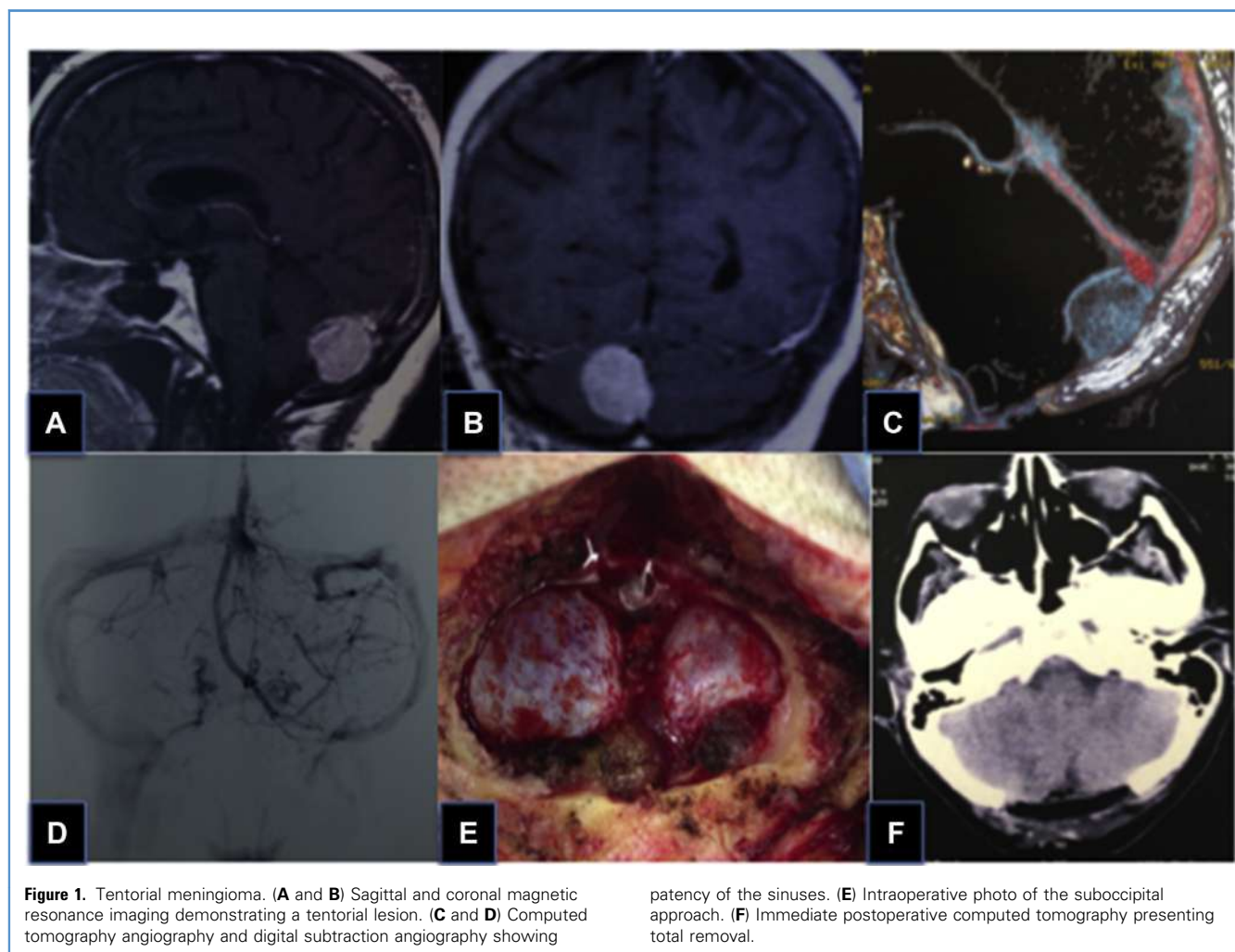
clinoidal meningioma died as a result of clinical and pulmonary disturbances during the postoperative period. Morbidities were related to definite unilateral olfactory nerve deficits in 2 olfactory groove meningiomas. CSF leakage occurred in 3 cases, including 1 tentorial lesion, 1 petroclival lesion, and 1 foramen magnum meningioma. Hemiparesis occurred in 1 case with a petroclival meningioma. The more conservative surgical removal approach in the older group leads to a lower morbidity and a better overall outcome, as presented in **Tables 2** and **3**.

In the younger group, the mortality was 4% owing to a pulmonary infection and sepsis in 1 case with a giant petroclival meningioma. Owing to the small number of cases, there was no statistical relevance in the difference observed between the 2 groups except in age, which reflects the selection criteria, and the Simpson grade I resection for younger patients. The Simpson grade was related to the more aggressive removal employed to obtain a higher local control, considering the expectation of a longer follow-up period for this group. There was no statistical difference between the groups considering Glasgow Outcome

Scale scores 4 and 5. **Table 3** summarizes the Glasgow Outcome Scale scores of both groups.

During the same period of the present study, 86 patients with skull base meningiomas were operated on. Cases excluded from the control group were lesions with distinct topography, size, surgical approaches, previous surgical treatment, and such aspects that would lead to serious statistical bias. We operated on 6 patients in the elderly group with meningiomas of <3 cm. One case was a clinoidal meningioma invading the optic canal with progressive visual disturbance. A second patient presented with a tuberculum sellae meningioma with chiasmatic compression. A third case was a foramen magnum meningioma compressing the medulla. In these 3 cases, we avoided any modality of radiation owing to the neural structures involved in the tumors. The other 3 cases were patients who presented with documented growth of petroclival meningiomas.

Radiosurgery is also a reasonable alternative for such locations according to the results observed in the literature.¹⁷ Nevertheless, our first choice is surgical removal to obtain definite control of



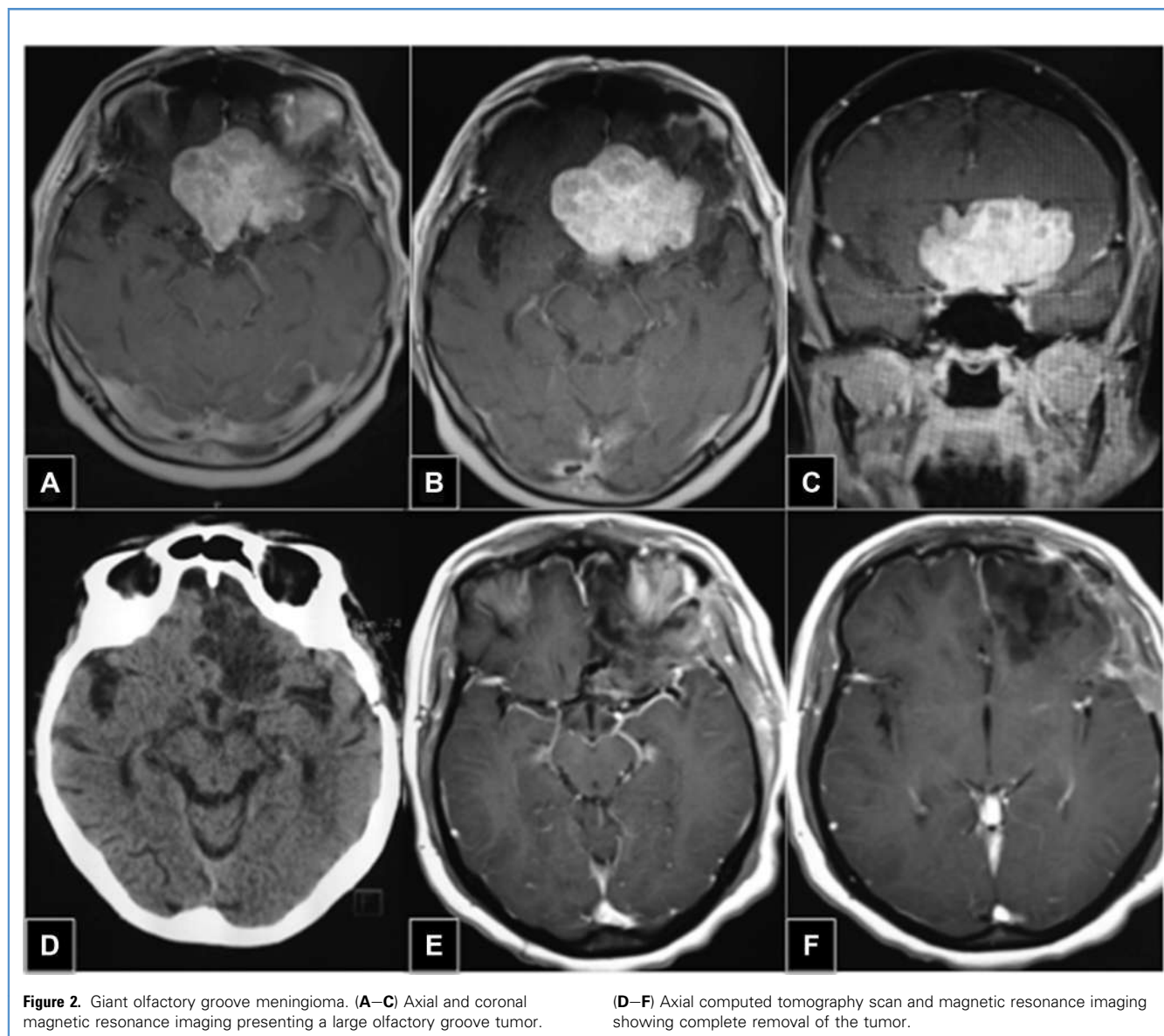


Figure 2. Giant olfactory groove meningioma. (A–C) Axial and coronal magnetic resonance imaging presenting a large olfactory groove tumor.

(D–F) Axial computed tomography scan and magnetic resonance imaging showing complete removal of the tumor.

such small meningiomas and to assess the cytogenetic and molecular profile of the tumors. We discussed the alternatives with the patients, and surgery was performed according to the patient's preference.

Postoperative Considerations

Our current protocol for managing meningiomas after surgical removal considers the Simpson grade, World Health Organization (WHO) grade, and molecular cytogenetics in the prediction of recurrence.^{14-16,18-20} We follow patients with benign meningiomas (WHO grade I); depending on the diagnosis of recurrence, we consider surgical removal as the first treatment option. We consider radiosurgery when surgical removal is not possible, the cytogenetic profile is unfavorable, and growth of the meningioma is documented. In elderly patients, medical

conditions and comorbidities are also considered. When these aspects exclude patients as candidates for surgery, radiosurgery is performed in cases of documented growth or recurrence. In our department, radiosurgery is avoided as the first option for benign meningiomas and as an immediate adjuvant therapy even in cases of less radical surgeries. Exceptions for primary radiosurgery include asymptomatic elderly patients with documented growth of a cavernous sinus meningioma. If the optic nerve exhibits normal function and is a safe distance from the tumor, we recommend radiosurgery to control the disease. If the optic nerve or any other cranial nerves are disturbed, we recommend surgical decompression of the optic canal and peeling of the lateral wall of the cavernous sinus in an attempt to improve the cranial nerve function followed by complementary radiosurgery.

Table 3. Glasgow Outcome Scale Scores

Score	Age ≥ 65 (n = 23)	Age < 65 (n = 23)
5	20 (87)	15 (65.2)
4	0	6 (26.1)
3	1 (4.3)	1 (4.3)
2	0	0
1	2 (8.6)	1 (4.3)

Data are presented as number (%).

Depending on the molecular findings and the proliferation index, residual tumors remain stable and without recurrence over long periods in favorable cases.^{5,7,20-23} In cases that have undergone radical removal, local control is even better, which justifies the avoidance of submitting patients to irradiation and following the cases over many years.^{5,7,10,11,18-22} We consider these aspects

very important in the follow-up of elderly patients after surgical removal. In atypical meningiomas (WHO grade II), if a Simpson grade I or II resection is achieved, close follow-up with MRI every 3 months for 2 years and every 6 months in the third year is recommended. If there is evidence of recurrence, surgical removal whenever possible followed by radiosurgery is the first-choice approach in our department. In malignant meningiomas, the most radical resection possible is followed by radiosurgery. A more recent study presented a similar algorithm for the treatment of WHO grade II and III meningiomas.^{20,24-26}

CONCLUSIONS

The present study suggests that elderly patients with symptomatic skull base meningiomas should be considered for surgical treatment owing to the acceptable morbidity of such procedures. Previous comorbidities, clinical and cardiologic evaluations, involvement of major venous sinuses, and arterial encasement are important factors that should be considered in the decision regarding the extent of the surgical resection.

REFERENCES

- Hashimoto N, Rabo C, Okita Y, Kinoshita M, Kagawa N, Fujimoto Y, et al. Slower growth of skull base meningiomas compared with non-skull base meningiomas based on volumetric and biological studies. *J Neurosurg.* 2012;116:574-580.
- Niiri M, Yatsushiro K, Nakamura K, Kawahara Y, Kuratsu J. Natural history of elderly patients with asymptomatic meningiomas. *J Neurol Neurosurg Psychiatr.* 2000;68:25-28.
- Sughrue ME, Rutkowski MJ, Aranda D, Barani JJ, McDermott MW, Parsa AT. Treatment decision making based on published natural history and growth rate of small meningiomas. A review and meta-analysis. *J Neurosurg.* 2010;113:1036-1042.
- Kongland A, Rogne SG, Helseth E, Meling TR. Meningioma in the very old-validating prognostic scoring systems. *Acta Neurochir (Wien).* 2013;155:2263-2271.
- Schul DB, Wolf S, Krammer MJ, Landscheidt JF, Tomasino A, Lumenta CB. Meningioma surgery in the elderly: outcome and validation of 2 proposed grading score systems. *Neurosurgery.* 2012;70:555-565.
- Black P, Kathiresan S, Chung W. Meningioma surgery in the elderly: a case-control study assessing morbidity and mortality. *Acta Neurochir (Wien).* 1998;140:1013-1016.
- Jääskeläinen J. Seemingly complete removal of histologically benign intracranial meningioma: late recurrence rate and factors predicting recurrence in 657 patients. A multivariate analysis. *Surg Neurol.* 1986;26:461-469.
- Almefly R, Dunn IF, Pravdenkova S, Abolfotoh M, Al-Mefly O. True petroclival meningiomas: results of surgical management. *J Neurosurg.* 2014;120:40-51.
- Ildan F, Erman T, Göçer AL, Tuna M, Bağdatoğlu H, Cetinalp E, et al. Predicting the probability of meningioma recurrence in the preoperative and early postoperative period: a multivariate analysis in the midterm follow-up. *Skull Base.* 2007;17:157-171.
- Obeid F, Al-Mefly O. Recurrence of olfactory groove meningiomas. *Neurosurgery.* 2003;53:534-543.
- Sughrue ME, Kane AJ, Shangari G, Rutkowski MJ, McDermott MW, Berger MS, et al. The relevance of Simpson grade I and II resection in modern neurosurgical treatment of World Health Organization grade I meningiomas. *J Neurosurg.* 2010;113:1029-1035.
- Simpson D. The recurrence of intracranial meningiomas after surgical treatment. *J Neurol Neurosurg Psychiatry.* 1957;20:22-39.
- Kinjo T, Al-Mefly O, Kanaan I. Grade zero removal of supratentorial convexity meningiomas. *Neurosurgery.* 1993;33:394-399.
- Oya S, Sade B, Lee JH. Sphenoorbital meningioma: surgical technique and outcome. *J Neurosurg.* 2011;114:1241-1249.
- Oya S, Kawai K, Nakatomi H, Saito N. Significance of Simpson grading system in modern meningioma surgery: integration of the grade with MIB-1 labeling index as a key to predict the recurrence of WHO grade I meningiomas. *J Neurosurg.* 2012;117:121-128.
- da Silva CE, de Freitas PE. Large and giant skull base meningiomas: the role of radical surgical removal. *Surg Neurol Int.* 2015;6:113.
- da Silva CE, Peixoto de Freitas PE. Recurrence of skull base meningiomas: the role of aggressive removal in surgical treatment. *J Neurol Surg B Skull Base.* 2016;77:219-225.
- Sekhar LN, Juric-Sekhar G, Brito da Silva H, Pridgeon JS. Skull base meningiomas: aggressive resection. *Neurosurgery.* 2015;62(suppl 1):30-49.
- Combs SE, Ganswindt U, Foote RL, Kondziolka D, Ton JC. State-of-the-art treatment alternatives for base of skull meningiomas: complementing and controversial indications for neurosurgery, stereotactic and robotic based radiosurgery or modern fractionated radiation techniques. *Radiat Oncol.* 2012;7:226.
- Choy W, Kim W, Nagasawa D, Stramotas S, Yew A, Gopen Q, et al. The molecular genetics and tumor pathogenesis of meningiomas and the future directions of meningioma treatments. *Neurosurg Focus.* 2011;30:1-12.
- Al-Mefly O, Topsakal C, Pravdenkova S, Sawyer JR, Harrison MJ. Radiation-induced meningiomas: clinical, pathological, cytogenetic, and cytogenetic characteristics. *J Neurosurg.* 2004;100:1002-1013.
- da Silva CE, Peixoto de Freitas PE. Classification of meningiomas based on their surgical removal, World Health Organization grade, and cytogenetic profile: a treatment algorithm. *World Neurosurg.* 2017;105:289-293.
- Ketter R, Henn W, Niedermayer I, Steilen-Gimbel H, König J, Zang KD, et al. Predictive value of progression-associated chromosomal

- aberrations for the prognosis of meningiomas: a retrospective study of 198 cases. *J Neurosurg.* 2001; 95:601-607.
24. Rigel BT, Jensen RL. Molecular genetics of meningiomas. *Neurosurg Focus.* 2005;19:1-8.
25. Jung HW, Yoo H, Paek SH, Choi KS. Long-term outcome and growth rate of subtotally resected petroclival meningiomas: experience with 38 cases. *Neurosurgery.* 2000;46:567-574.
26. Sun SQ, Hawasli AH, Huang J, Chicoine MR, Kim AH. An evidence-based treatment algorithm for the management of WHO grade II and III meningiomas. *Neurosurg Focus.* 2015;38:E3.

Conflict of interest statement: The authors declare that the article content was composed in the absence of any commercial or financial relationships that could be construed as a potential conflict of interest.

Received 20 May 2018; accepted 4 September 2018

Citation: World Neurosurg. (2018).

<https://doi.org/10.1016/j.wneu.2018.09.024>

Journal homepage: www.WORLDNEUROSURGERY.org

Available online: www.sciencedirect.com

1878-8750/\$ - see front matter © 2018 Elsevier Inc. All rights reserved.